

Role of ultrasound in congenital cataract: Our experience

Ayat Aziz Al-Alwan (1)
Hazim Kamil Haddad (1)
Rana Ahmad Alkrimeen (1)
Mohammad Jalal Alsa'aideh (2)
Mu'taz Ghalib Halasah (1)

(1) Jordanian Royal Medical Service, Radiology Department, Amman, Jordan

(2) Jordanian Royal Medical Service, Ophthalmology Department, Amman, Jordan

Correspondence:

Rana Ahmad Alkrimeen, MD
 Jordanian Royal Medical Service,
 Radiology Department
 Amman,
 Jordan
 Tel: 00962776200373,
Email: rana.alkrimeen@yahoo.com

Received: November 2018; Accepted: December 2018; Published: January 1, 2019

Citation: Ayat Aziz Al-Alwan, Hazim Kamil Haddad, Rana Ahmad Alkrimeen, Mohammad Jalal Alsa'aideh, Mu'taz Ghalib Halasah. Role of ultrasound in congenital cataract: Our experience. World Family Medicine. 2019; 17(1): 4-9.

DOI: 10.5742MEWFM.2019.93593

Abstract

Aim: To evaluate the role of ultrasound in congenital cataract.

Method: 242 patients aged less than one year referred from pediatric ophthalmologists in our hospital (Queen Rania Children Hospital) with clinical suspicion of congenital cataract over the period June 2015 till December 2017 were evaluated by orbital ultrasound to evaluate the posterior chamber.

Patients were divided into 2 groups: the first group, 169 patients who presented with bilateral congenital cataract (69.8%) and the second group 73 patients who presented with unilateral congenital cataract (30.2%).

Results: Of the first group of patients (bilateral congenital cataract): 130 patients (76.9%) had normal posterior chamber on ultrasound bases.

39 patients (23.1%) had abnormal posterior chamber; 24 patients (66.6%) had retinal detachment, 12 patients (25.74%) had vitreous hemorrhage, 2 patients (5.1%) had posterior staphyloma and 1 patient (2.56%) had bilateral persistent hyperplastic primary vitreous.

Of the patients in the second group (unilateral congenital cataract): 44 patients (60.3%) had normal posterior chamber and 29 patients (39.7%) had abnormal posterior chamber, 15 patients (51.7%) had retinal detachment, 8 patients (27.6%) had persistent hyperplastic primary vitreous, 5 patients (17.2%) had vitreous hemorrhage and 1 patient (3.5%) had retinoblastoma.

Conclusion: Ultrasound is a valuable diagnostic modality in assessing the posterior chamber in patients with unilateral or bilateral congenital cataract to rule out associated posterior chamber abnormalities which will influence the prognosis and management plan.

Key words: Ultrasound, congenital cataract, posterior chamber.

Background / Introduction

Cataract is the opacification of the normally transparent crystalline lenses, and is considered rare in the paediatric age group [1]. Paediatric cataracts are classified as congenital, developmental, or traumatic; it is considered congenital when found in the first year of life while the developmental occur after infancy. Cataract is one of the preventable and curable causes of visual disability. Approximately affecting 200 thousand children worldwide, with the prevalence of 3-6/10 thousand life births [2-4]. In addition to the clinical examination; ultrasonography plays a role in discovering and detecting any pathology in the posterior part of the globe in dense cataract and helps in guiding the ophthalmologist to approach pre-operatively [5]. Ultrasound was first used in ophthalmology in 1956 by the American ophthalmologists Mundt and Hughes [6].

Materials and Methods

This is a retrospective study for infants who were suspected to have congenital cataract at Queen Rania Children hospital. All patients were scanned with Philips Ultrasound machine using linear high frequency transducer (3-9) MHZ in the period from June 2015 to December 2017. We included all infants (less than one year) with suspected congenital cataract, either unilateral or bilateral and isolated or associated with other abnormalities, excluding premature and trauma patients. No special preparation was needed to perform orbital ultrasound, where it is considered a straightforward procedure. The exam is started by closing the patient's eye and scanning directly through the eyelid using ultrasound gel to ensure adequate visualization. The two standard views were taken; involving the transverse and sagittal dimensions and was completed by color Doppler flow if there is suspicion of tumor or vascular lesion. All

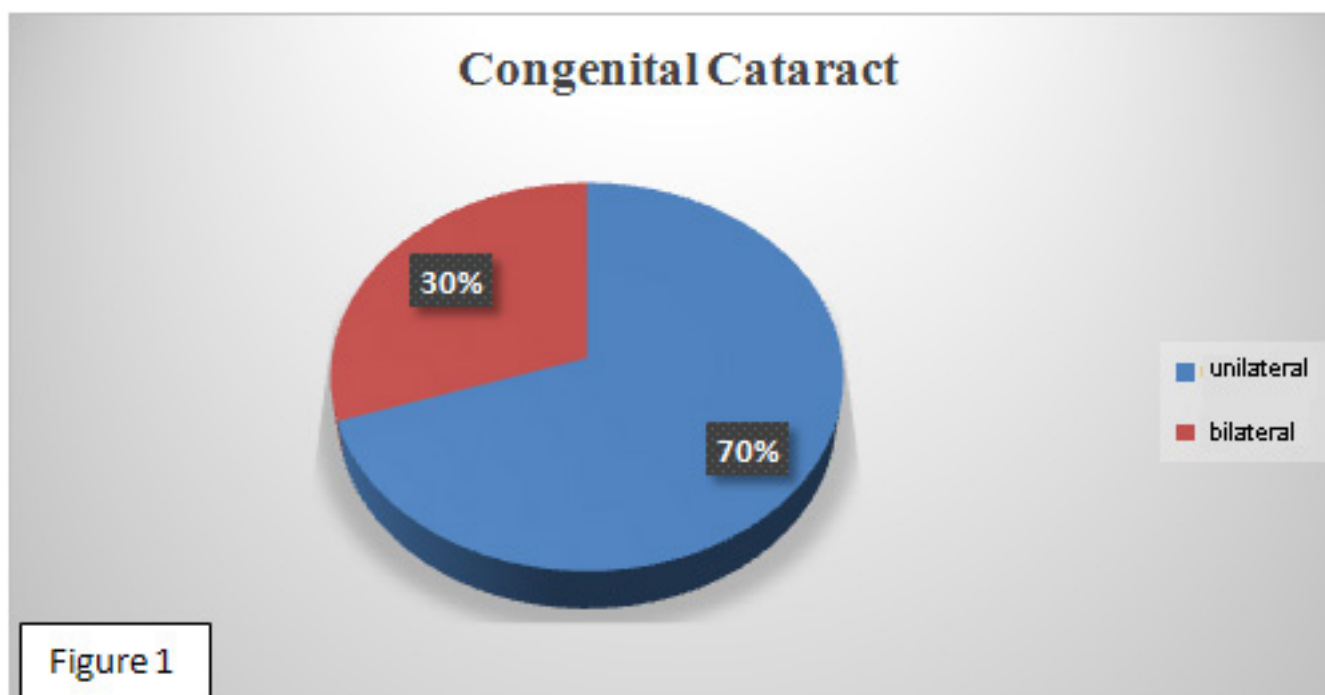
patients were examined by two pediatric ophthalmologists and two pediatric radiologists in two separate sessions and the results were analyzed by simple statistical method.

Ethical concern

Our study had ethical committee approval from our institution and all data was obtained lawfully.

Results

The total number of the sample was 242 patients and the age group included less than one year regardless of the gender. All underwent orbital ultrasound to assess posterior chamber in patients who have congenital cataract. The study revealed that ultrasound is a valuable method for detecting posterior chamber pathology. The patients were divided into two groups: the first group (bilateral congenital cataract) which included 169 patients (69.8%) and the second group (unilateral congenital cataract) which included 73 patients (30.2%) (Figure 1). In both groups the majority of patients were not found to have any pathology in the posterior chamber on ultrasound bases in that: 130 patients (76.9%) in the first group and 44 patients (60.3%) in the second group. In the first group about 39 patients (23.1%) had posterior chamber pathology where (Figure 2) 24 patients (66.6%) had retinal detachment (Figure 3), 12 patients (25.74%) had vitreous hemorrhage, 2 patients (5.1%) had posterior staphylocoma and one patient (2.56%) had bilateral persistent hyperplastic primary vitreous. While in the second group 29 patients (39.7%) had posterior chamber pathology where (Figure 4) 15 patients (51.7%) had retinal detachment, 8 patients (27.6%) had bilateral persistent hyperplastic primary vitreous (Figure 5), 5 patients (17.2%) had vitreous hemorrhage and one patient (3.5%) had retinoblastoma (Figure 6).



Bilateral congenital cataract

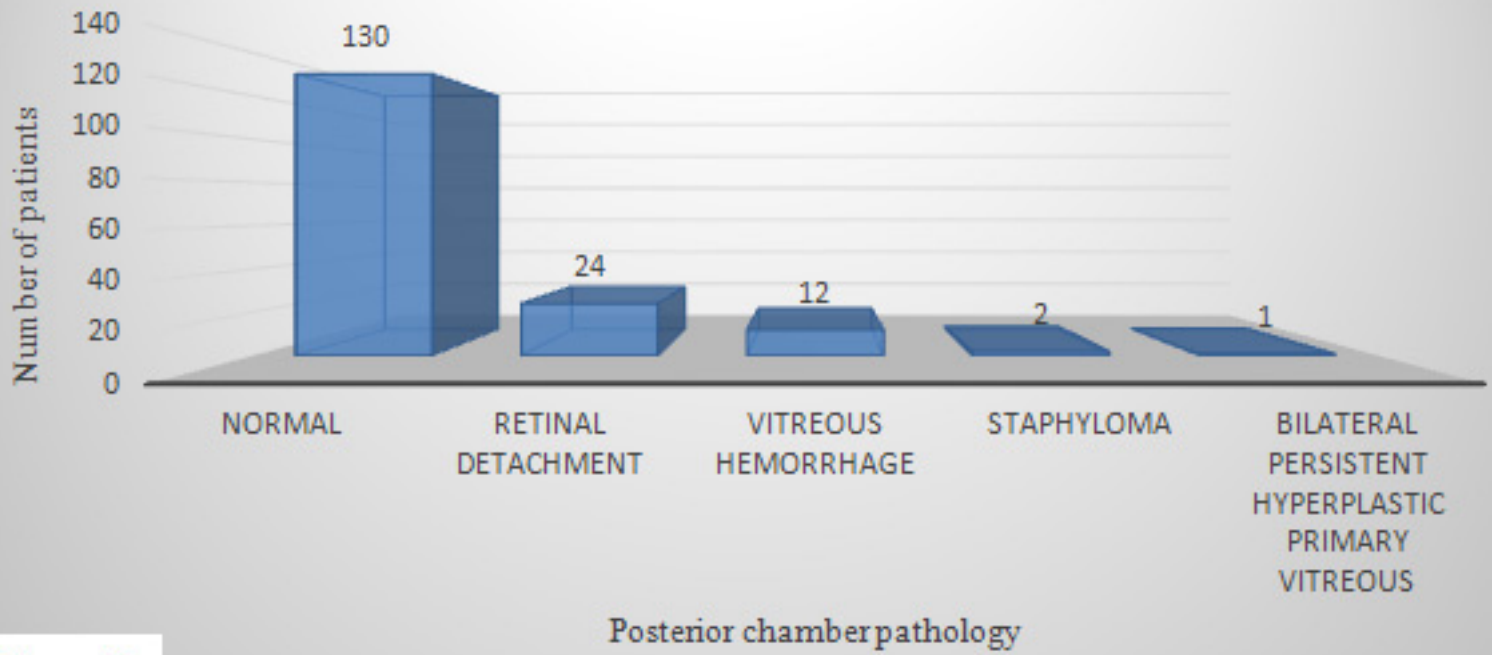


Figure 2

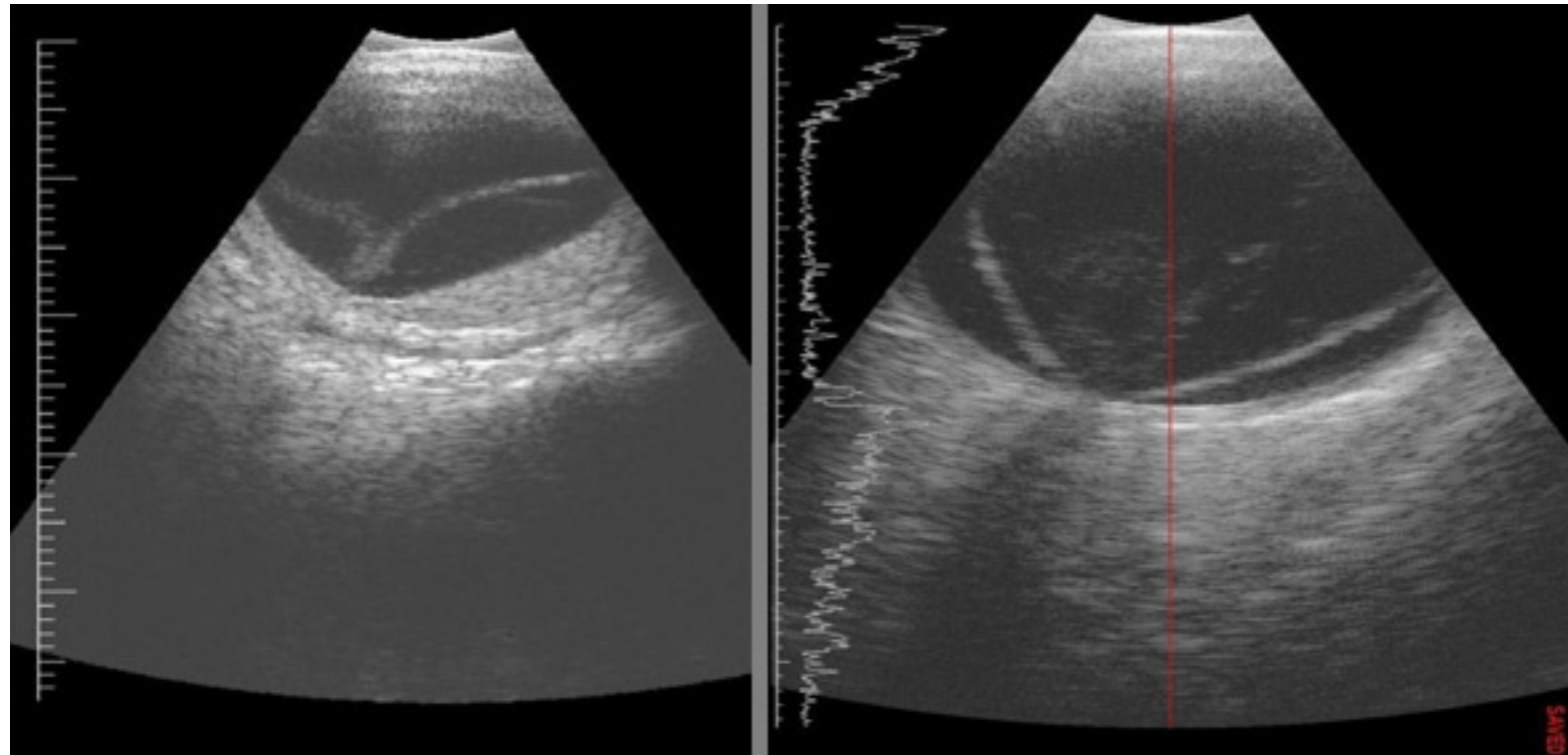


Figure 3, Ultrasound shows bilateral retinal detachment in 6 months baby with bilateral cataract

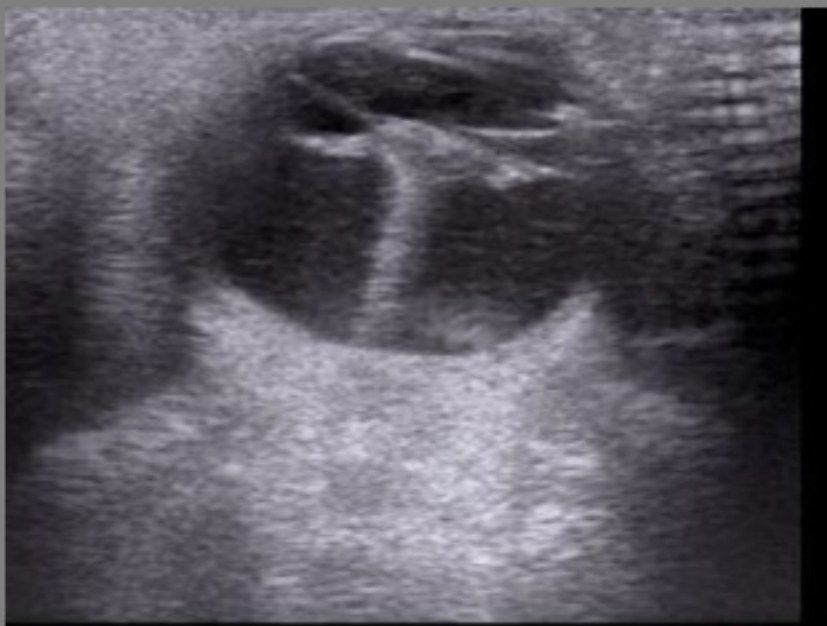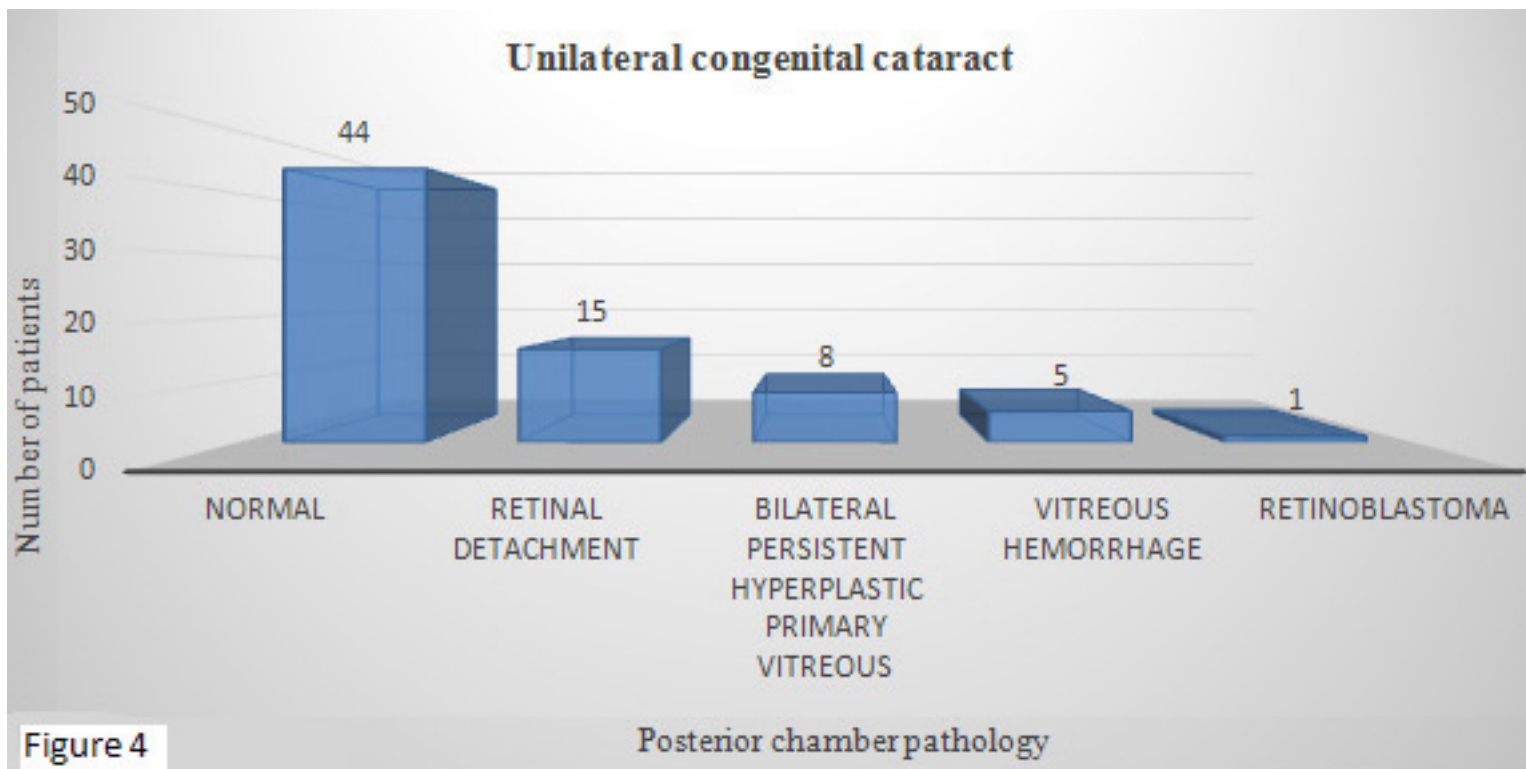


Figure 5, Ultrasound shows persistent hyperplastic primary vitreous in 4 months baby with unilateral cataract.

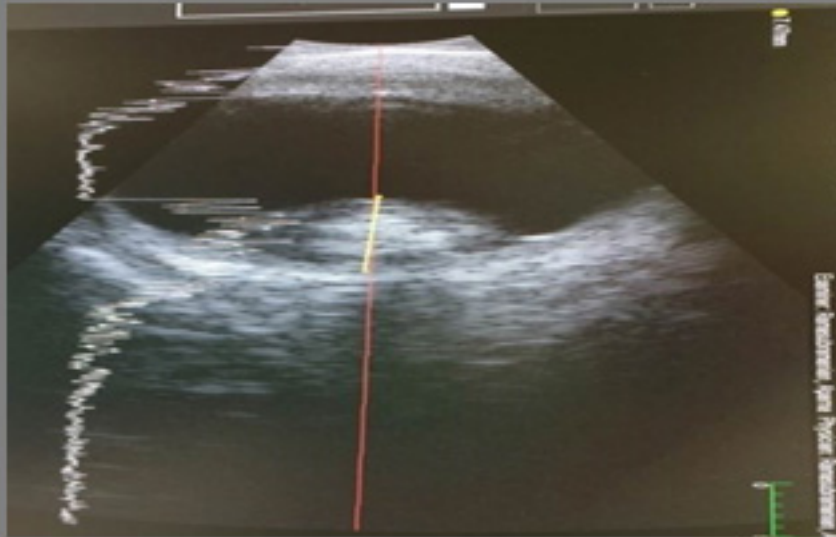

Figure 6, Ultrasound shows retinoblastoma in 3 months baby with unilateral cataract.

Discussion

As there were no previous studies that had a similar experience (the role of ultrasound in infants who were suspected to have congenital cataract), we share our experience in highlighting the importance of the ultrasound as a non invasive and informative modality. A cataract is an opacification of the lens; if the cataract is diagnosed in the first year of life it is considered congenital, which is divided into unilateral or bilateral. The unilateral is usually sporadic, though it may be associated with trauma or infection (intrauterine) in a minority of cases, while the bilateral is often inherited and may be associated with other disease. The possible underlying causes are intrauterine infection, trisomy and hypoglycemia. Due to that genetic and metabolic workup are required [7]. The congenital cataract may cause significant visual impairment that eventually, if not treated, may lead to blindness, in spite of that fortunately, it is a treatable and preventable disease if diagnosed early. The diagnosis of cataract requires a detailed history and prompt ocular examination, including anterior segment exam by indirect ophthalmoscope and intraocular pressure measurement using air puff, in addition as a complementary orbital ultrasound might be required, especially if there is a dense cataract. Our study revealed that more than half of the patients showed normal posterior chamber in both groups; while when there is posterior chamber pathology, the second group, is countered with a higher percentage than the first group in about 40%. In both groups; the retinal detachment is the most common posterior chamber pathology in about 67% in the first group and 52% in the second group. The vitreous hemorrhage is the second common finding in the

first group, about 26%, while it is the third common in the second group, about 17%. The minority of patients in the first group had bilateral persistent hyperplastic primary vitreous with a percentage of 2.6% and this pathology is considered the second most common in the second group, about 28%. In the first group the patients had staphyloma in a percentage of 5% which was not found in the second group; the same for retinoblastoma that was found in the second group in a minority of patients, about 3.5%, and not found in the first group.

Limitation: It was a single center study and without taking into consideration the gender, in addition to that the ultrasound is operator dependent.

Conclusion

Ultrasound is a non invasive, valuable and reliable method to assess the posterior chamber in patients with congenital cataract and help the surgeon to map the surgery accurately. It is considered a complementary method to the traditional ophthalmic examination. Further studies are warranted.

References

- 1- Amanda Churchill¹, Jochen Graw. Clinical and experimental advances in congenital and pediatric cataracts. doi:10.1098/rstb.2010.0227.
- 2- Anagha Medsinge, Ken K Nischal. Pediatric cataract: challenges and future directions. doi.org/10.2147/OPTH.S59009.
- 3- Foster A, Gilbert C, Rahi J. Epidemiology of cataract in childhood: a global perspective. *J Cataract Refract Surg.* 1997;23 Suppl 1:601–604.
- 4- Holmes JM, Leske DA, Burke JP, Hodge DO. Birth prevalence of visually significant infantile cataract in a defined US population. *Ophthalmic Epidemiol.* 2003;10(2):67–74.
- 5- Stayte M, Reeves B, Wortham C. Ocular and vision defects in preschool children. *Br J Ophthalmol.* 1993;77(4):228–232.
- 6- Mundt GH, Hughes WF. Ultrasonics in ocular diagnosis. *Am J Ophthalmol.* 1956; 41: 488-98.
- 7- Mounir Bashour. Congenital Cataract. Updated: Aug 17, 2018